

Entübe Bir Hastada Trakeobronşiyal Sisteme Yerleştirilmiş Nazogastrik Tüp

Tracheobronchially Placed Nasogastric Tube in an Intubated Patient

Trakeobronşiyal Sisteme Yerleştirilmiş Nazogastrik Tüp / Tracheobronchially Placed Nasogastric Tube

Suat Gezer, Bekir Sami Karapolat

Medical Faculty of Düzce University, Clinic of Thoracic Surgery, Düzce, Türkiye.

A 27 years old male patient was referred to our hospital with traumatic asphyxia due to a job accident. He had been intubated before the admission. He was hospitalized in the intensive care unit and a nasogastric tube was inserted. However, radiological investigations showed that the tube was passed just near the endotracheal tube and placed in the tracheobronchial system (Figure 1,2).

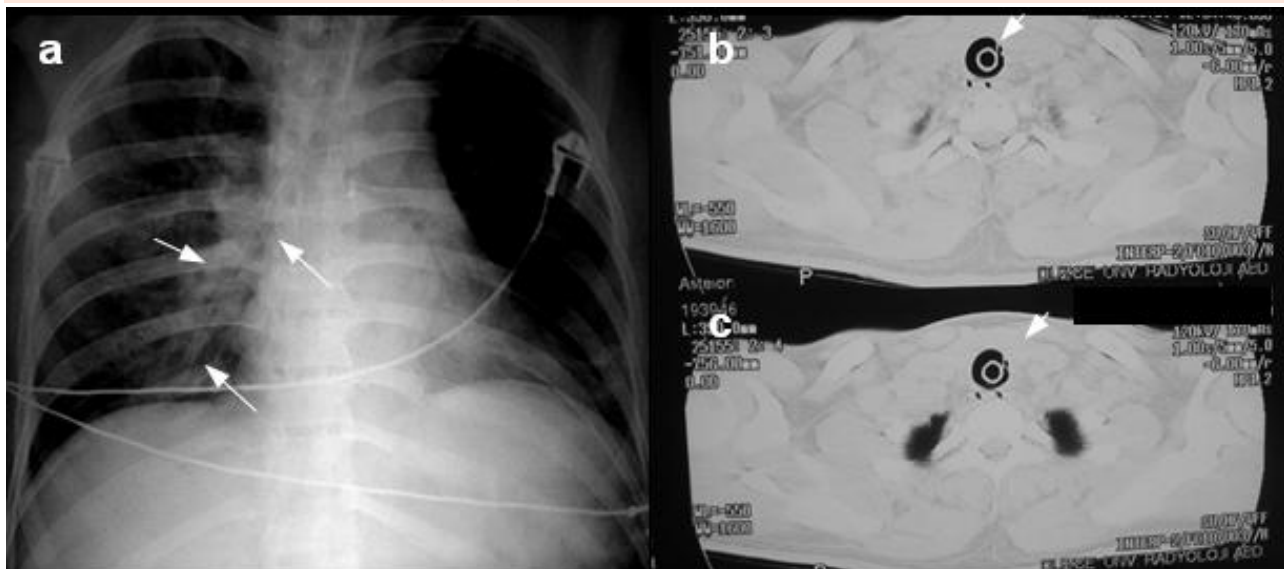


Figure 1. (a) Chest x-ray presenting endotracheal tube and a thinner tube (nasogastric tube) in the trachea and right main bronchus (b and c) Thoracic CT presenting endotracheal tube and a nasogastric tube in the trachea.

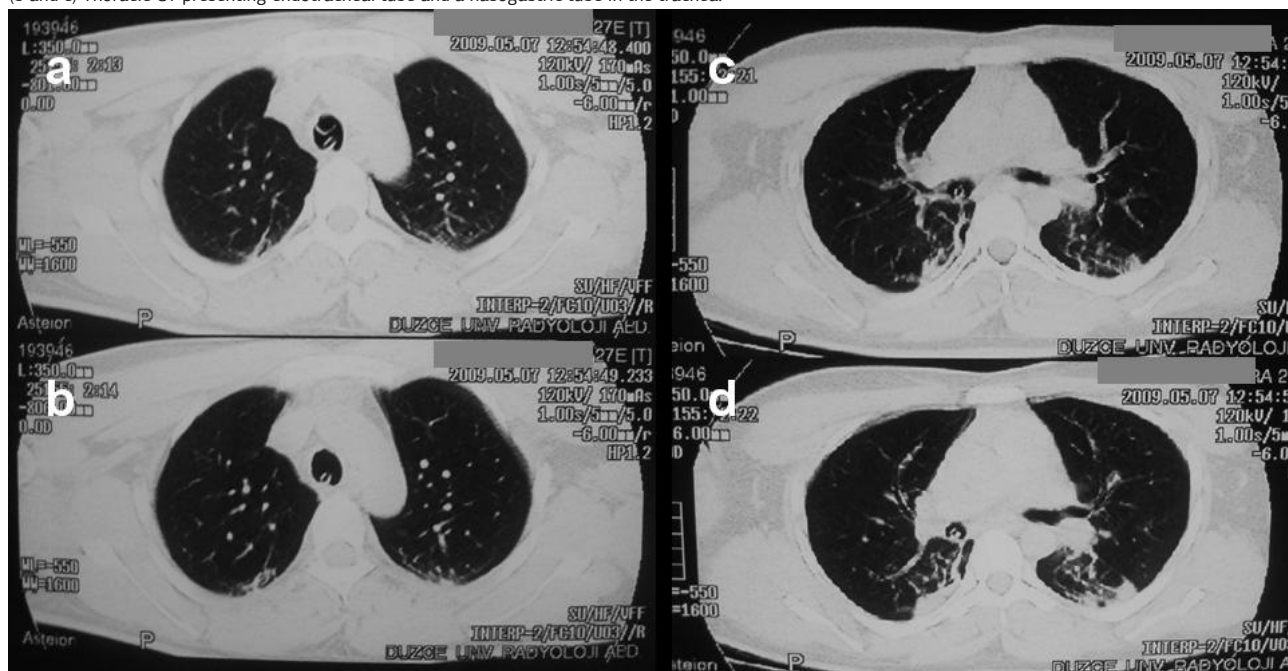


Figure 2. (a) Thoracic CT presenting endotracheal tube and a nasogastric tube in the trachea (b) Thoracic CT presenting nasogastric tube in the trachea (c) Thoracic CT presenting nasogastric tube in the right main bronchus (d) Thoracic CT presenting nasogastric tube in the intermediate bronchus.

DOI: 10.4328/JCAM.10.3.31 Received: 09.03.2010 Accepted: 17.03.2010 Printed: 01.09.2010

Corresponding author: Suat Gezer, Düzce Üniversitesi Tıp Fakültesi, Göğüs Cerrahisi AD. 81620, Konuralp, Düzce, Türkiye.

E-mail : Suatdr@hotmail.com